
Clare Rusbridge BVMS PhD DipECVN MRCVS
European and RCVS and European Specialist In Veterinary Neurology

Stone Lion Veterinary Centre

41 High Street,
Wimbledon,
London, SW19 5AU

Tel: +44 (0)208 946 4228

E-mail: neuro.vet@btinternet.com

Date - 27/11/2008

To whom it may concern:

This is to confirm that on the above date the magnetic resonance images (MRI) obtained on 4th August 2008 from the Blenheim cavalier King Charles spaniel detailed below were reviewed

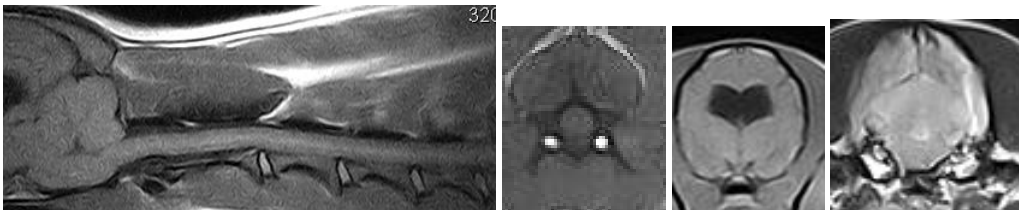
Little Colani's Balae
Registration number VDH-ICC 05/4661

DOB: 13th July 2005
Sex: female
Microchip: 276098100-794149
Owner: S Haas

These images reveal:

Chiari-like malformation of the caudal skull	YES
Syringomyelia in the cervical spinal cord	NO
Central canal dilatation	NO
Ventricular dilatation	Marked

Mucoid material in **both** tympanic bullae



Using the informal CKCS CM/SM classification the grade of **A** would be attributed to this individual.

Clare Rusbridge BVMS PhD DipECVN MRCVS
RCVS and European Specialist In Veterinary Neurology