

---

**Reported by Clare Rusbridge** BVMS PhD DipECVN MRCVS  
European and RCVS and European Specialist In Veterinary Neurology  
**Stone Lion Veterinary Hospital**  
41 High Street,  
Wimbledon,  
London, SW19 5AU  
Tel: +44 (0)208 946 4228

---

Date: 28/11/2011

To whom it may concern:

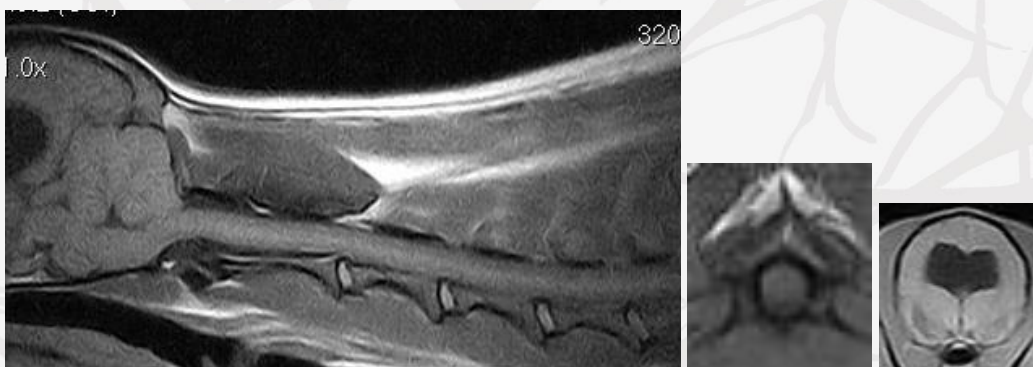
This is to confirm that on the above date the magnetic resonance images (MRI) of **Little Colani's Gladdys** (Gladdys)– **VDH-ICC 09/6014** obtained on **20<sup>th</sup> October 2011** were reviewed

**Blenheim CKCS female, DOB 21<sup>st</sup> March 2009**, microchip 276098102592105

Owner – **S Haas**

These images reveal:

Chiari like malformation of the caudal skull	<b>YES</b>
Dilatation of the central canal / syringomyelia	<b>NO</b>
Ventricular dilatation	<b>MARKED</b>
Mucoid material in tympanic bullae	<b>NO</b>



This dog was **2.6 years old** at the time of scanning. Using the informal CKCS classification scheme the grade of **A** would be attributed to this individual.

Clare Rusbridge BVMS PhD DipECVN MRCVS  
RCVS and European Specialist In Veterinary Neurology

For information on all aspects of syringomyelia visit  
<http://www.veterinary-neurologist.co.uk>

CR